平成２３年度三重県精度管理調査結果

一般検査

フォトサーベイ結果

担当：平塚　美子
松田ふき子

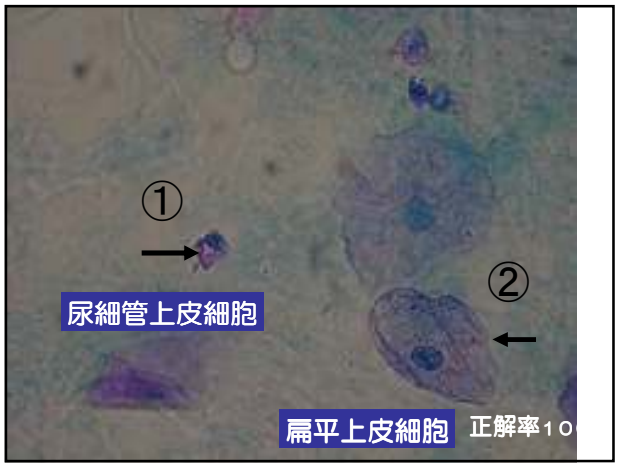

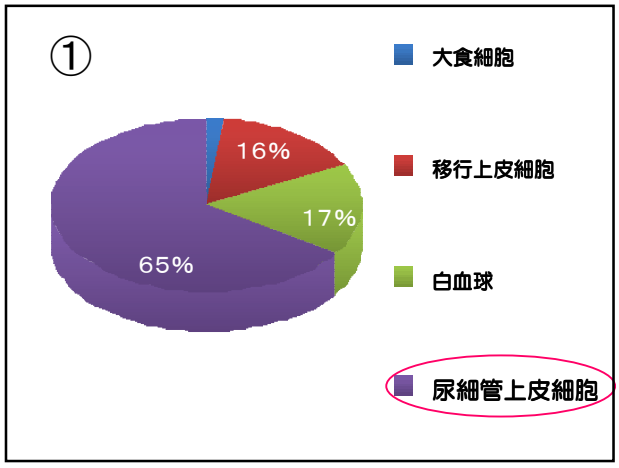

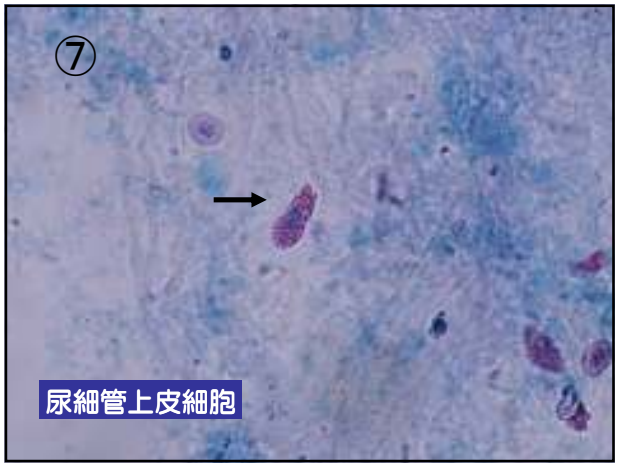

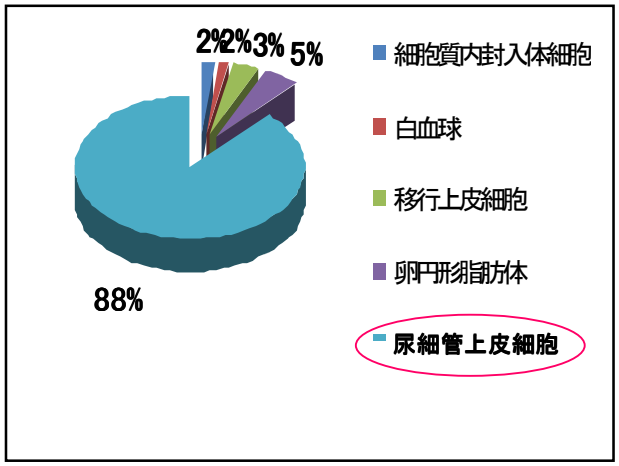

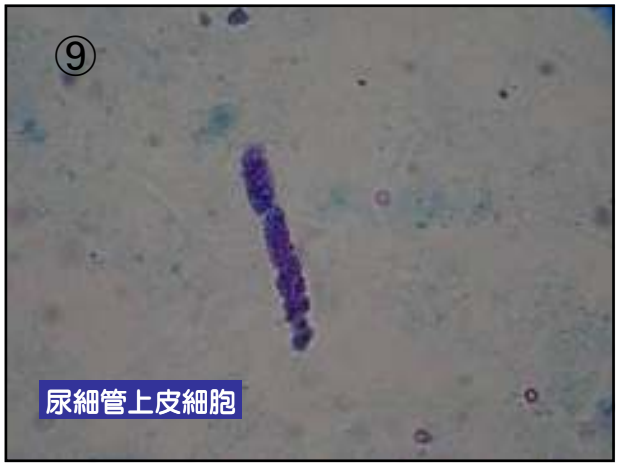

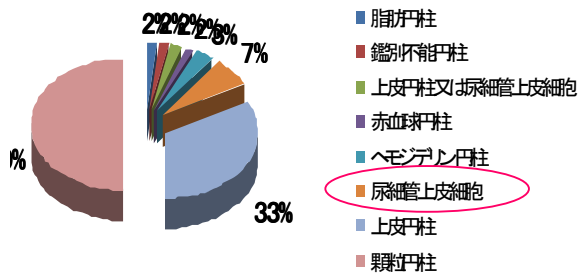

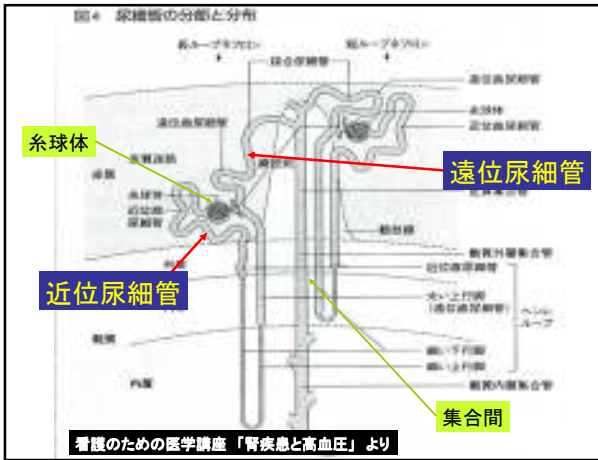

看護のための医学講座「腎疾患と高血圧」より

遠位尿細管

近位尿細管

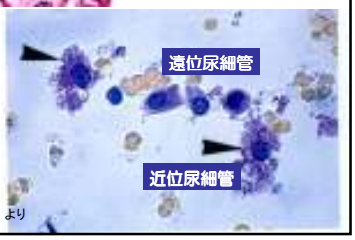

尿沈渣検査のすすめ方:西 国広 編著 より

近位尿細管細胞

細胞質は粗い顆粒状
細胞のかたちは不定形
核を認めない細胞も多い

遠位尿細管細胞

細胞質は細かい顆粒状
細胞のかたちは類円形、多角形
辺縁は平滑
核は濃縮状で偏在性

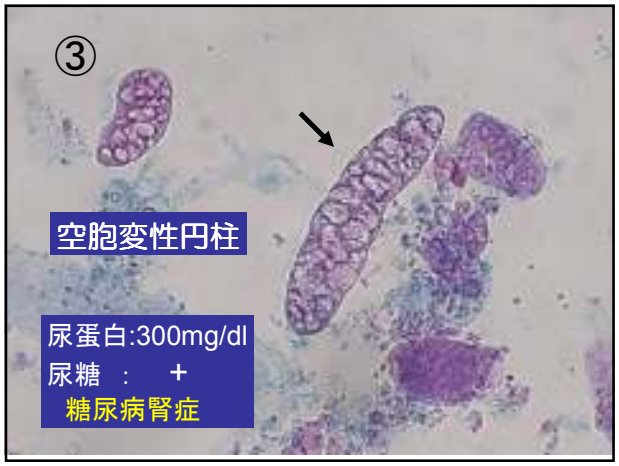

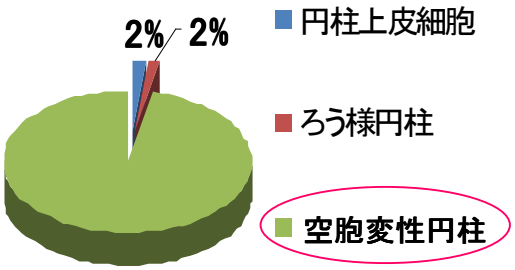

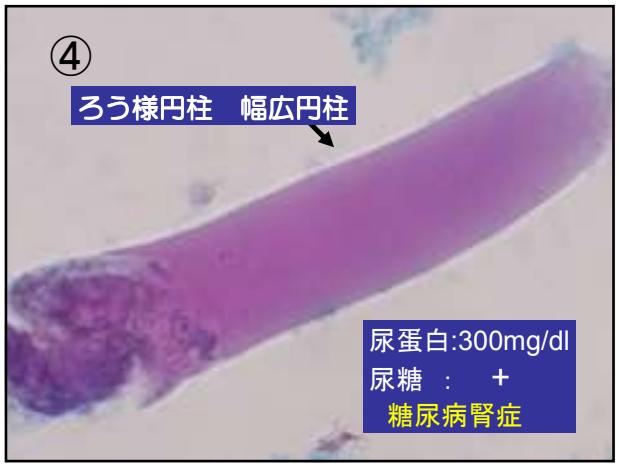
④
ろう様円柱　幅広円柱
尿蛋白:300mg/dl
尿糖　：　＋
糖尿病腎症

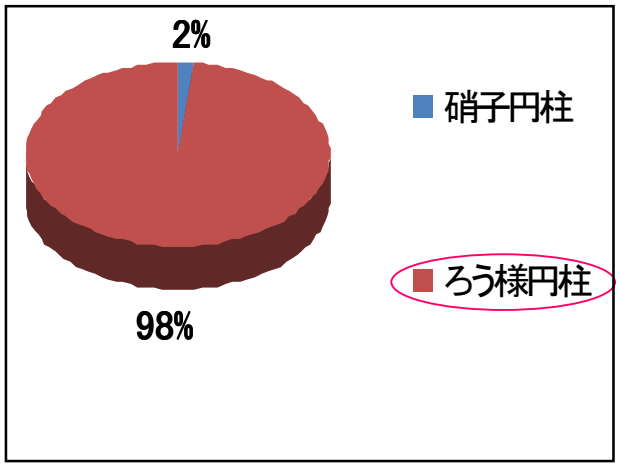
2%
98%
硝子円柱
ろう様円柱

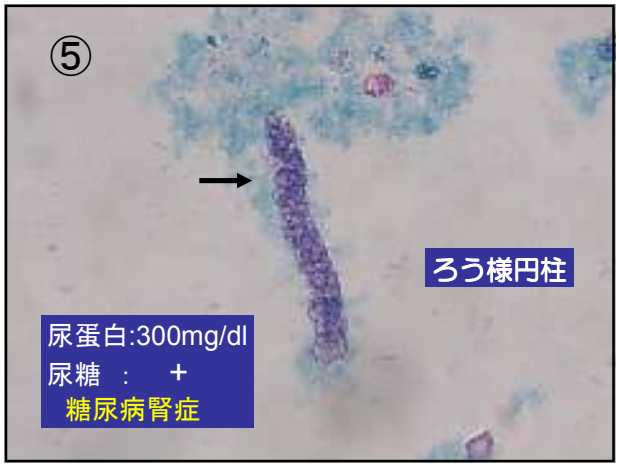
⑤
ろう様円柱
尿蛋白:300mg/dl
尿糖　：　＋
糖尿病腎症

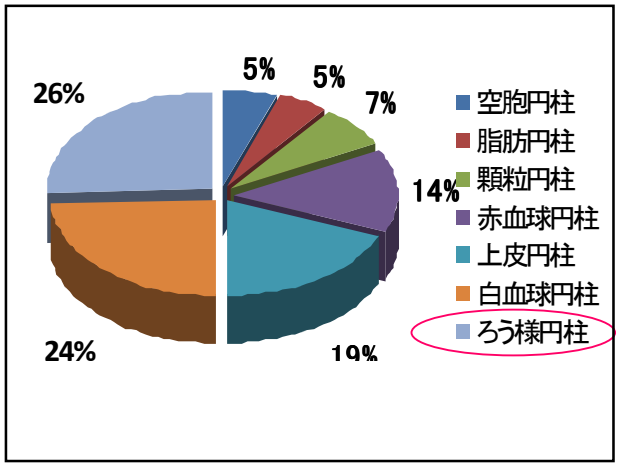
26%
5%
5%
7%
14%
24%
19%
空胞円柱
脂肪円柱
顆粒円柱
赤血球円柱
上皮円柱
白血球円柱
ろう様円柱

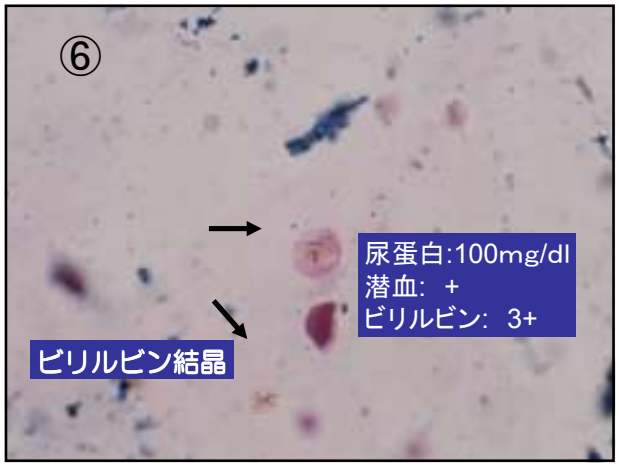
⑥
尿蛋白:100mg/dl
潜血:　+
ビリルビン:　3+
ビリルビン結晶

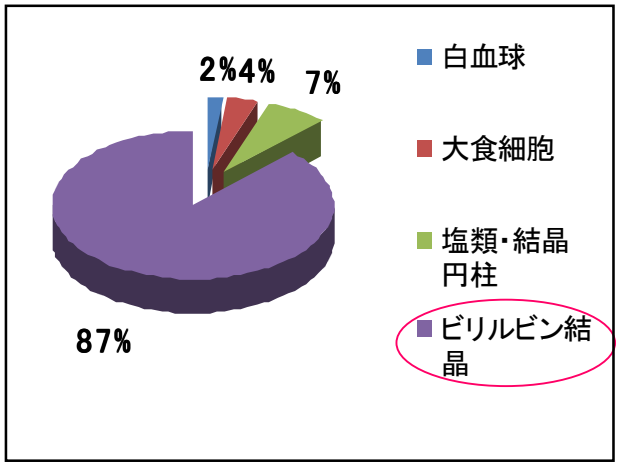
2%
4%
7%
87%
白血球
大食細胞
塩類･結晶円柱
ビリルビン結晶

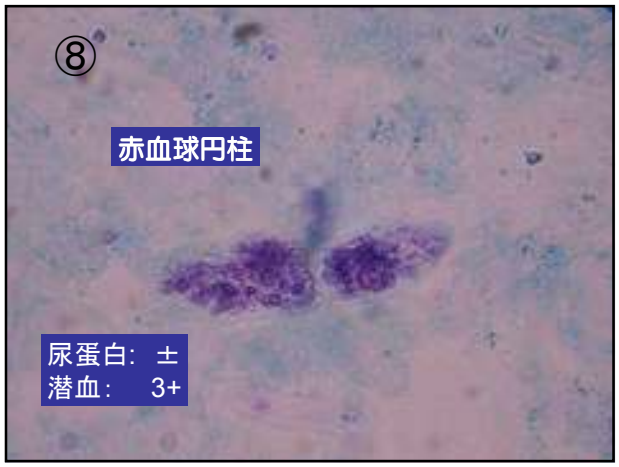
⑧
赤血球円柱
尿蛋白: ±
潜血: 3+

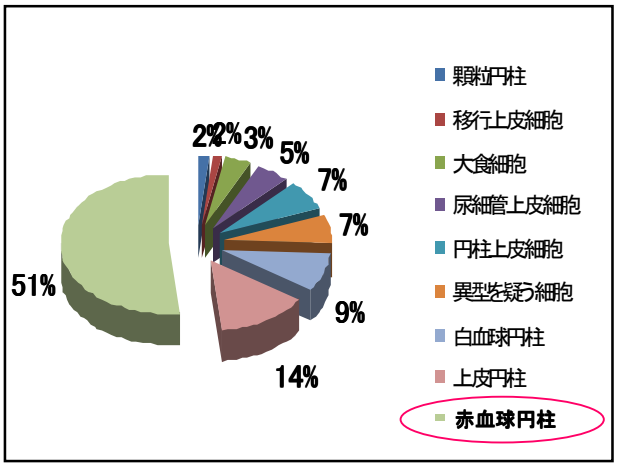
2%
2%
3%
5%
7%
7%
9%
14%
51%
顆粒円柱
移行上皮細胞
大食細胞
尿細管上皮細胞
円柱上皮細胞
異型性疑う細胞
白血球円柱
上皮円柱
赤血球円柱